



ISSN: 0976-3376

Available Online at <http://www.journalajst.com>

ASIAN JOURNAL OF
SCIENCE AND TECHNOLOGY

Asian Journal of Science and Technology
Vol. 15, Issue, 11, pp. 13200-13203, November, 2024

RESEARCH ARTICLE

HOMOEOPATHIC MANAGEMENT FOR SYSTEMIC LUPUS ERYTHEMATOSUS

***Dr. Nooreen Mohammadi**

Head Medical Services, Banjara Hills Branch, Dr Batra's Positive Health Clinic Pvt. Ltd., BHMS, FCHD

ARTICLE INFO

Article History:

Received 18th August, 2024
Received in revised form
19th September, 2024
Accepted 17th October, 2024
Published online 23rd November, 2024

Keywords:

Systemic Lupus Erythematosus (SLE),
Autoimmune, Homeopathy.

ABSTRACT

Systemic Lupus Erythematosus (SLE) is a chronic autoimmune condition characterized by inflammation and damage to various body systems, including the skin, joints, kidneys, heart, and lungs. Homeopathy provides relief by stimulating body's natural healing processes. This paper presents the case of a professional singer from Texas who, despite conventional treatments continued to suffer from severe illness but after she opted for homeopathy, her improvement was significant as well as discontinuation of steroid use within two months was achieved. This case highlights the potential benefits of homeopathy in managing SLE.

Citation: Dr. Nooreen Mohammadi. 2024. "Homoeopathic management for Systemic Lupus Erythematosus", *Asian Journal of Science and Technology*, 15, (11), 13200-13203.

Copyright©2024, Dr. Nooreen Mohammadi. This is an open access article distributed under the Creative Commons Attribution License, which permits unrestricted use, distribution, and reproduction in any medium, provided the original work is properly cited.

INTRODUCTION

SLE is a disorder where the immune system attacks healthy tissues, causing damage the skin, joints, kidneys, heart, and lungs etc. Its exact cause is unknown, but genetics play a major role. SLE symptoms include fatigue, joint pain, skin rashes, and fever. If left untreated the complications can be severe, affecting the heart, kidneys, and nervous system, and significantly impacting the quality of life

CASE PROFILE

A 38-year-old female came to Dr Batra's with complaints of red rashes on her arm and neck for the past year, accompanied by a burning sensation, weakness, and fatigue since 8-10 months. These symptoms started after covid vaccination. She is currently taking hydroxychloroquine 200 mg and ibuprofen, but despite taking steroids, there has been no relief from her symptoms. The rashes are tiny red malar lesions with raised edges on the border, located on her neck and arms. Her symptoms were itching and redness, but there is no discharge.

Past treatments: Allopathy T/T - hydroxychloroquine 200 mg, ibuprofen - Temporary relief of symptoms by using corticosteroids.

Past medical history: Raynaud's.

Family history: RA - Grandmother.

Physical Generals

Diet	Mixed
Appetite	Moderate
Desire	Sweets ++
Aversion	Not specific
Thermal Reaction	Hot patient++
Thirst	Moderate - 2 to 2 and half litres
Stools	Constipated, unsatisfactory
Urine	Normal
Perspiration	Profuse - all over the body
Sleep	Refreshing - 7 to 8 hours
Dreams	Forgetful

Mental Generals: The patient lives in Texas, USA, and is a singer by profession. She is often worried about her health due to inflammation in her body, along with redness on her arms and neck. She is unable to focus on her work. As a singer, she needs to be energetic to perform, but her professional life has been greatly disturbed by these issues. She used to take steroids, but despite this, her symptoms persisted.

Case analysis: Repertorial totality.

Repertory used	Rubrics selected
Phatak Repertory	<ul style="list-style-type: none"> - A/F VACCINATION ILL EFFECTS OFF - CONSCIENCE TROUBLE FROM - ANXIETY. - ERUPTIONS TENDENCY TO ERYTHEMATOSUS - SKIN - BURNING - CRAVINGS FOR SWEETS

Repertory screenshot

	1	2	3	4	5	6	7	8	9	10	11	12	13	14	15	16	17	18	19	20	21	22	23	24	25
4. Clipboard 4	8	6	4	3	2	3	2	3	1	1	1	1	1	1	1	1	1	1	1	1	1	1	1	1	1
▶ 1. V - Vaccination, ill effects of agg (12) 1	3	2	3						3	3							1								1
▶ 2. S - Skin - burning, heat (16) 1	2	3	1	1		3	3						2	2	2	2		1	1					1	
▶ 3. E - Eruptions; tendency to - erythe... (3) 1	1	1			1																				
▶ 4. C - Craving - sweet things (16) 1	2			2	1			3			2	2								1	1	1			
▶ 5. C - Conscience - troubled, from, (an... (1) 1																							1		

Selection of Remedy: Sulphur 200 - 1 Dose & Alfa Alfa 6X

Miasmatic approach

Symptoms	Psora	Sycosis	Syphilis	Tubercular
ERYTHEMATOUS ERUPTIONS ON SKIN	+			
BURNING	+			
CRAVINGS FOR SWEETS	+			
Miasmatic predominance	Psora			

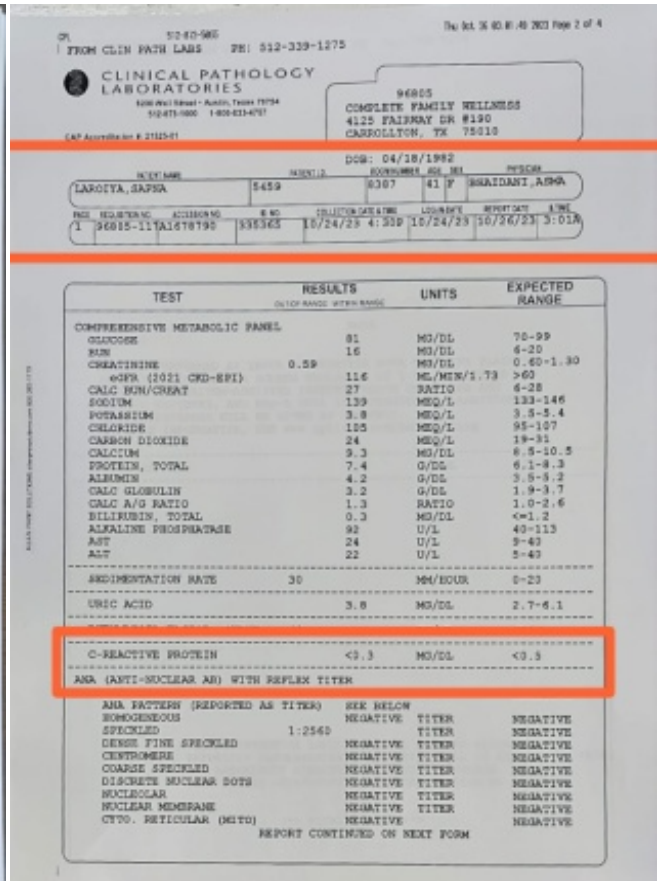
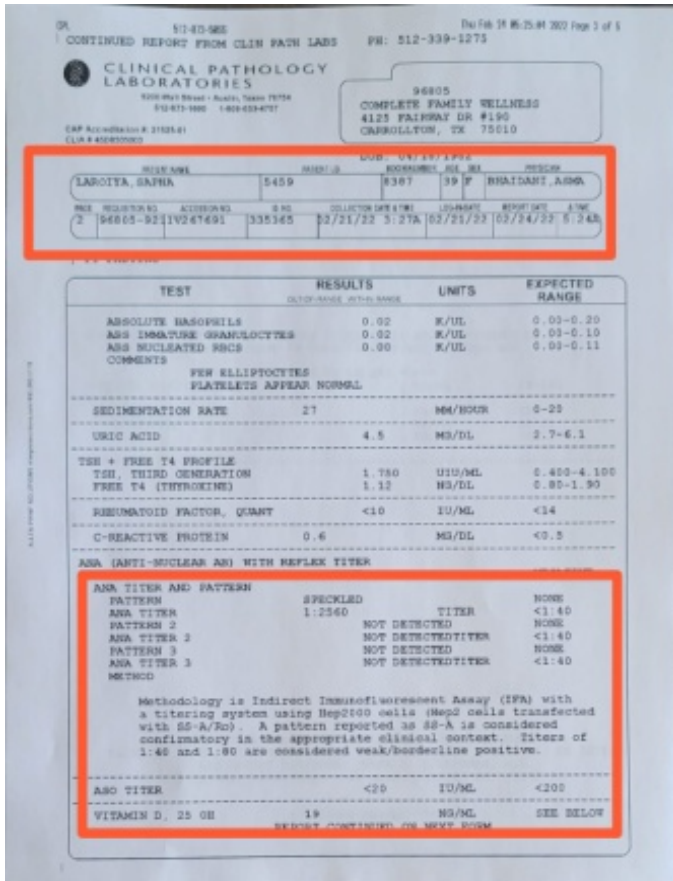
Investigations

BEFORE

The image displays two screenshots of medical reports. The left screenshot is a MyQuest lab report for patient LARQIYA, SAPNA. It lists various tests and their results, with several items highlighted in red boxes. The right screenshot is a Quest Diagnostics report for a THYROID PANEL WITH TSH, also for the same patient. This report includes results for TSH, Free T4, and Free T3, with the entire report area highlighted in a red box.

CRP: 0.6 (0.5); Rheumatoid Factor: <10 (14); Uric Acid: 4.5 (2.7-6.1); ANA Titre: 1:25 (1:40)

AFTER



CRP: 0.4 (<0.5);
 Uric Acid: 3.9 (2.7-6.1);
 ASO Titre: <20 (<200);

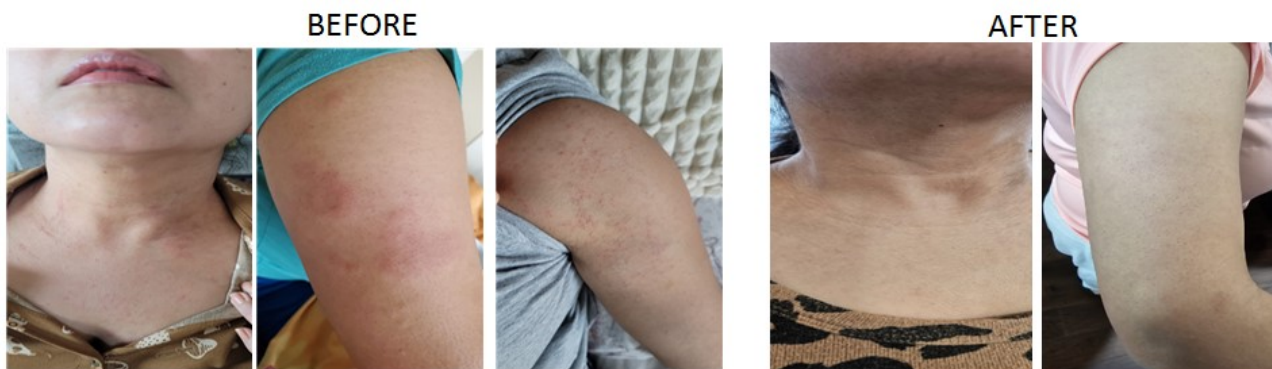A positive Anti nuclear Antibody (ANA) screen
 An elevated SM RNP antibody level at 8.0 (with a reference range indicating positive above 1.0)
 C-reactive protein level of 30.2, (above the normal range (less than 8.0)).
 Hepatitis B surface antibody immunity was low, at 5 L, indicating less than the protective threshold of ≥10 mIU/mL

RESULTS

Month	Progress	Prescription
1st month	After administering the constitution dose, corticosteroid medicines were stopped.	Sulph 200 1 dose followed by Saclac, Alfa Alfa 6X
2nd month	Weakness was present.	Saclac and Alfa Alfa 6X
3rd month	Serum creatinine decreased from 30.3 to 2.0.	Saclac and Alfa Alfa 6X
4th month	No rashes, no pain, no weakness.	Saclac and Alfa Alfa 6X
5th month	Stable overall.	Saclac and Alfa Alfa 6X
6th month	CRP: 0.6 (0.5); Rheumatoid Factor: <10 (14); Uric Acid: 4.5 (2.7-6.1); ANA Titre: 1:25 (1:40)	Sulph 200 1 dose followed by Saclac and Alfa Alfa 6X
7th month	Stable overall.	Saclac with Alfa Alfa 6X
8th month	Stable overall.	Saclac with Alfa Alfa 6X
9th month	Stable overall.	Saclac with Alfa Alfa 6X
10th month	CRP: 0.4 (<0.5); Uric Acid: 3.9 (2.7-6.1); ASO Titre: <20 (<200); Numbness in feet improved; No weakness; No skin rashes or itching; Not taking any steroids.	Saclac with Alfa Alfa 6X
11th month	No new complaints; stable overall.	Saclac with Alfa Alfa 6X
12th month	Stable overall.	Saclac with Alfa Alfa 6X

DISCUSSION & CONCLUSION

Despite using steroids, this 38-year-old female singer continued to experience persistent symptoms, including rashes, weakness, and pain, which severely impacted her ability to perform and diminished her quality of life. The conventional treatments failed to provide lasting relief, leaving her professional life disrupted. However with homeopathic treatment she experienced significant improvement. Her symptoms resolved, and she regained her energy and vitality, leading to a marked enhancement in her overall quality of life and professional performance.

The transformation**Feedback –**

←  **Sapna Laroiya TX**
1 review

★★★★★ 2 years ago

I live in USA, and taking treatment of LUPUS from Dr Batra's clinic and Dr Nooreen is taking care of me from last one year. I heard about this clinic and Dr Nooreen from one of my friend, who also live in USA and suffering from same disease.

I am very much satisfied with the treatment and the service. She always answer all my queries on time and treat like family members. I will strongly recommend this Clinic.

Acknowledgments: I take this opportunity to thank all those who have helped and supported me personally and professionally during this case process.

REFERENCES

1. Hahnemann S. Organon of medicine. B. Jain publishers; 2005.
2. Boericke W. Pocket manual of homoeopathic Materia Medica & Repertory: comprising of the characteristic and guiding symptoms of all remedies (clinical and pathogenetic) including Indian Drugs New Delhi, India: B Jain publishers; 2002.
3. Clarke JH. A dictionary of practical materia medica. 2 vols.[in 3]. 1900.
4. Kent JT. Lectures on homoeopathic materia medica. New Delhi, India: B Jain Publishing Company; 1980.
5. Lilienthal S. Homoeopathic therapeutics. B. Jain Publishers; 1998.
6. Kent JT. Lectures on Homeopathic Philosophy. Sittingbourne, Homeopathic Book Service. 1990.
7. Clarke JH. The Prescriber: A dictionary of the new therapeutics. Homeopathic Publishing Company; 1900.
